ORAL Pathology

Lesion

Morphologically altered tissue with objective signs of disease

Macule

Well circumscribed

flat area of altered coloration varying in size from a pinhead to several cms

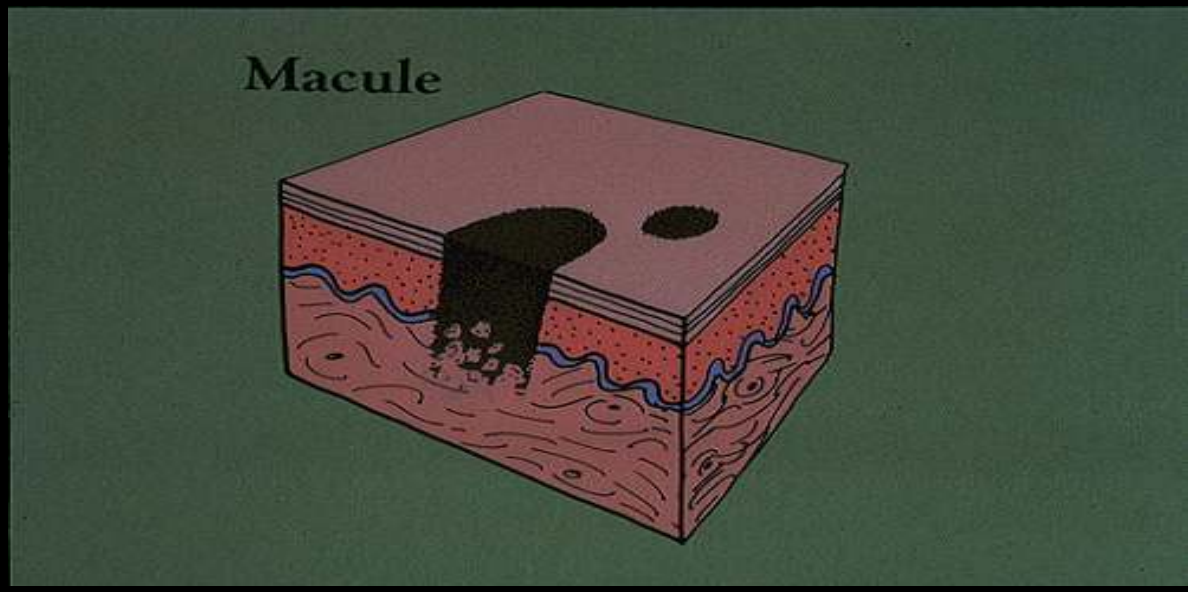

Macule

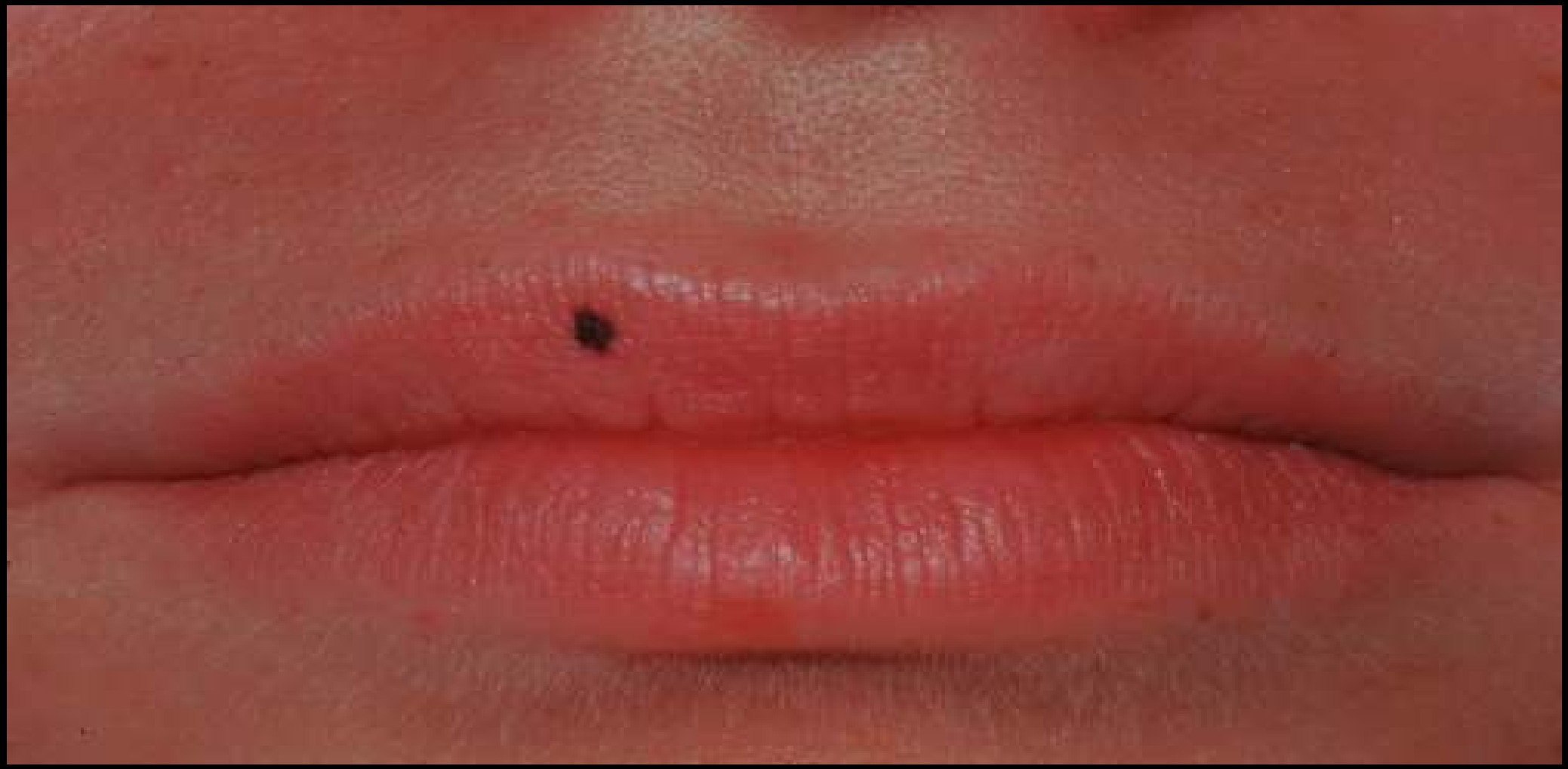

Macule/Patch

Papule

Small well circumscribed solid,elevated lesion less than

5 mm in diameter

Nodule

well circumscribed solid, elevated lesion more than 5 mm in diameter

Nodule

Plaque

Vesicle

Small well circumscrib
fluid filled lesion less th
5 mm
in diameter

Bulla

well circumscribed

fluid filled lesion larger than 5 mm

- in diameter.

Bullae

Pustule

well circumscribed
pus filled lesion
smaller than 5 mm
in diameter

Erosion

Break in the epithelium extending to but not involving the basal c layer

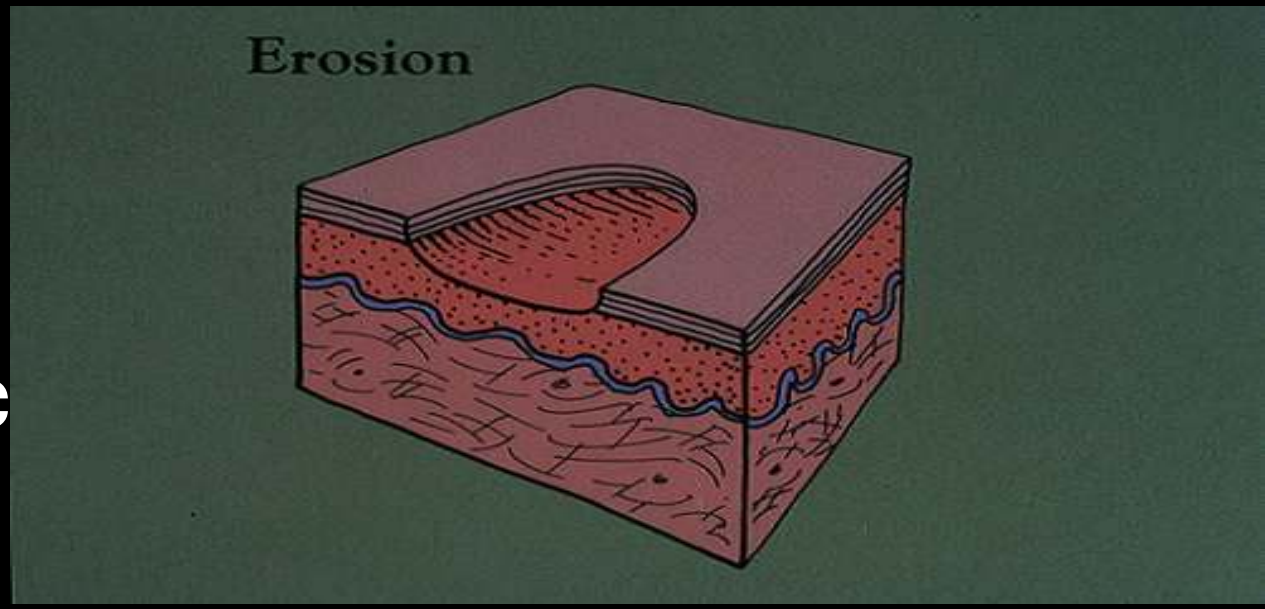

Erosion

Ulcer

Break in the continuity
of the entire epithelium
with the resultant exposure of
the underlying connective
tissue

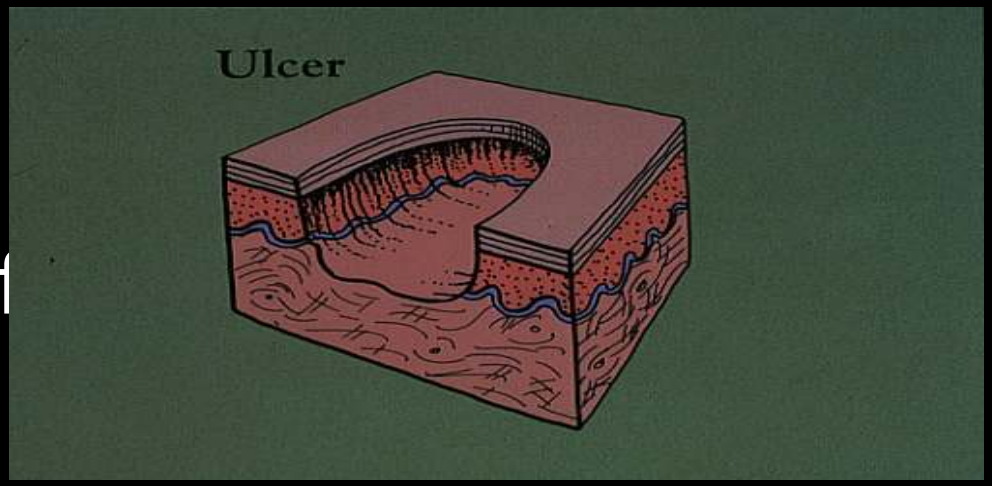

Ulcer

Pedunculated

Pedunculated

Sessile

Histologic terms

Hyperkeratosis

Thickening of the stratum corneum

Acanthosis

Thickening /Widening of the stratum spinosum

Acantholysis

Separation of cells in stratum spinosum resulting in intraepithelial split

definition

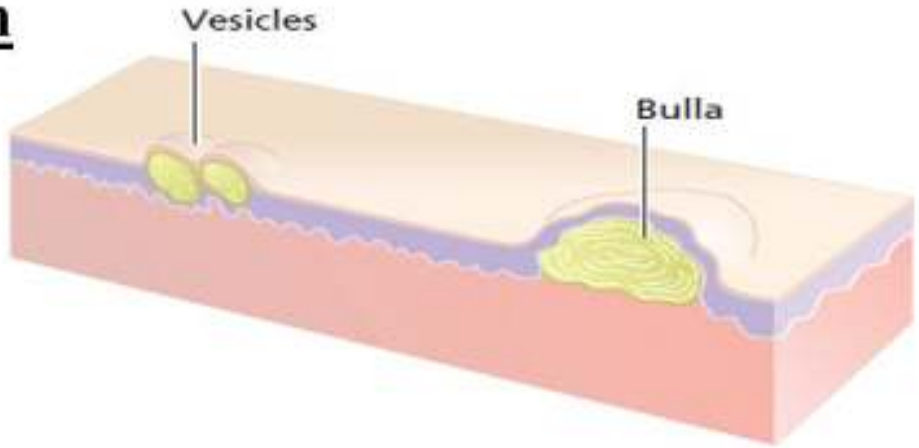

- Vesicles and bullae are raised lesions that contain fluid.
- A vesicle is less than 0.5 cm in diameter.
- A bulla is larger than 0.5 cm in diameter.

Bulla spreading test

- **Ulcer:** A defect or break in continuity of the mucosa that creates a punched-out area similar to a crater.

- **Pustule:** Similar in appearance to a blister, but it contains pus. Herpes simplex

Erosion of the soft tissue: is a partial loss of the epithelium

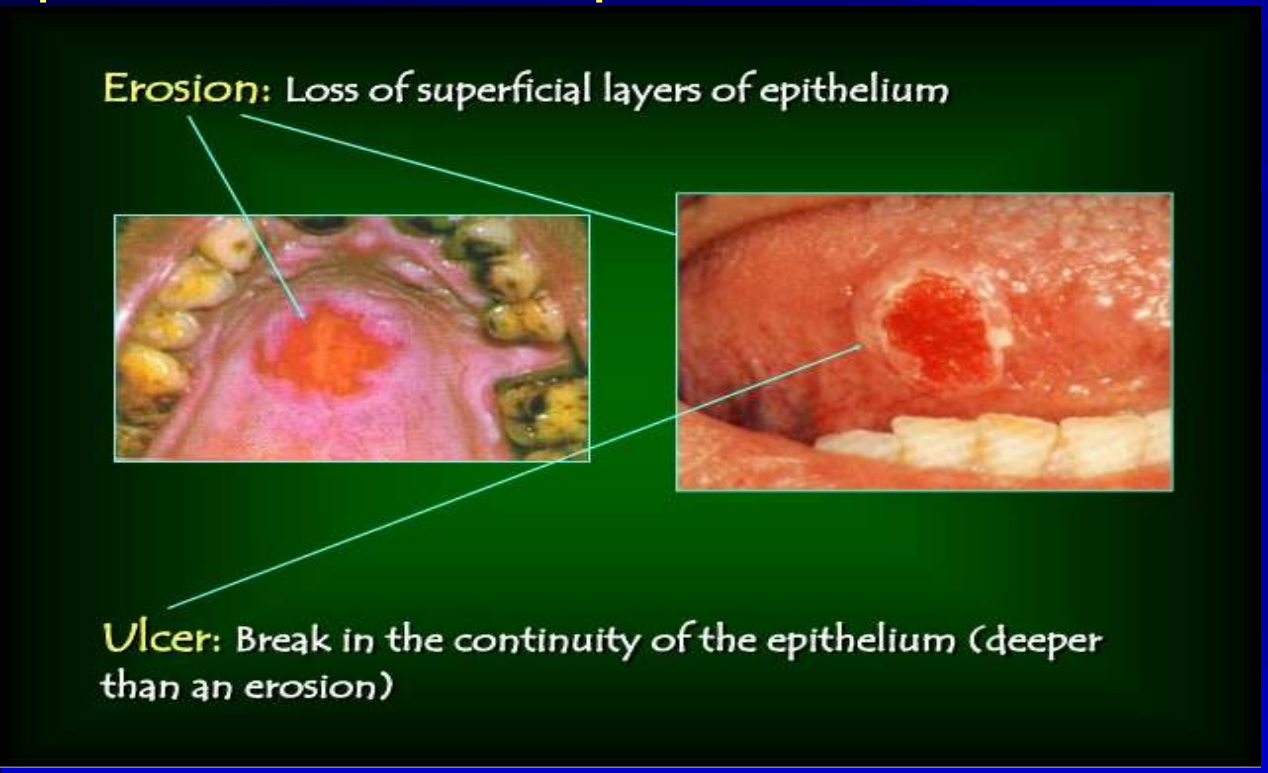

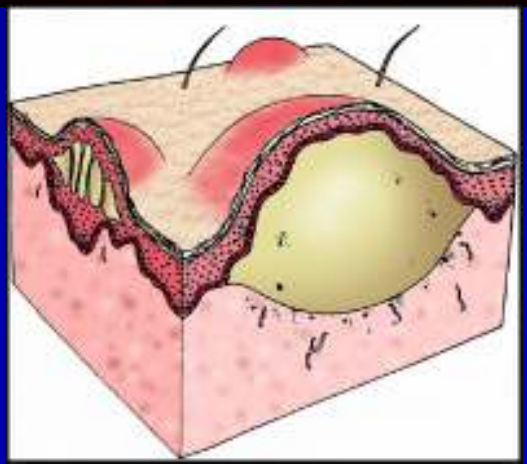

- **Purpura;** redish to purple discolorationmeasure 0.3–1 cm caused by leaking blood from vessels into C.T., these don't blanch when pressured, less than 0.3 cm **Petechia**.larger 1 cm **Ecchymosis**
- **Telangiectasia:** condition characterized by dilatation of the capillaries causing them to appear as small red or purple clusters, often spidery in appearance.

Infections

HSV

Herpes labialis

- ***Herpetic Whitlow*.** Herpetic whitlow is a **primary or a secondary HSV infection involving the finger(s)**. Before the universal use of examination gloves, this type of infection typically occurred in dental practitioners who had been in physical contact with infected individuals. **Contact could result in a vesiculoulcerative eruption on the digit (rather than in the oral region)**, along with signs and symptoms of primary systemic disease. **Pain, redness, and swelling are prominent with herpetic whitlow** and can be very pronounced. Vesicles or pustules eventually break and become ulcers. The duration of herpetic whitlow is protracted and may be as long as 4 to 6 weeks.

Primary herpetic whitlow

Herpes zoster

Herpangina

Hand, foot and mouth disease

acute necrotizing ulcerative gingivi

Management:

- Systemic metronidazole and oxygen-releasing agents topically. Followed by – a mechanical gingival treatment (scaling and root planning).
- Periodontal surgery to correct gingival and periodontal defects.

Syphilis

Figure 5-11 • Hutchinson's incisors of congenital syphilis. Dentition exhibiting crowns tapering toward the incisal edges. (From Halstead CL, Blozis GG, Drinnan AJ, Gier RE: *Physical evaluation of the dental patient*, St Louis, 1982, Mosby.)

Figure 5-12 • Mulberry molar of congenital syphilis. Maxillary molar demonstrating occlusal surface with numerous globular projections.

(candidiasis)